

See discussions, stats, and author profiles for this publication at: <https://www.researchgate.net/publication/223973443>

Death, nasomaxillary complex, and sleep in young children

Article in *European Journal of Pediatrics* · April 2012

DOI: 10.1007/s00431-012-1727-3 · Source: PubMed

CITATIONS

14

READS

13,927

2 authors:



Caroline Rambaud

Hôpital Raymond-Poincaré – Hôpitaux universitaires Paris Ile-de-France Ouest

124 PUBLICATIONS 3,213 CITATIONS

[SEE PROFILE](#)



Christian Guilleminault

Stanford University

1,033 PUBLICATIONS 79,567 CITATIONS

[SEE PROFILE](#)

Death, nasomaxillary complex, and sleep in young children

Caroline Rambaud · Christian Guilleminault

Posted by Geoff Bond
www.naturaleater.com

Received: 10 January 2012 / Accepted: 20 March 2012
© Springer-Verlag 2012

Abstract This is an investigation of anatomical and sleep history risk factors that were associated with abrupt sleep-associated death in seven children with good pre-mortem history. Seven young children with abrupt deaths and information on health status, sleep history, death scene report, and autopsy performed in a specialized unit dedicated to investigation of abrupt death in young children were investigated. Seven age and gender matched living children with obstructive-sleep-apnea (OSA) were compared to the findings obtained from the dead children. Two deaths results from accidents determined by the death scene and five were unexplained at the death scene. History revealed presence of chronic indicators of abnormal sleep in all cases prior death and history of an acute, often mild, rhinitis just preceding death in several. Four children, including three infants, were usually sleeping in a prone position. Autopsy demonstrated variable enlargement of upper airway soft tissues in all cases, and in all cases, there were features consistent with a narrow, small nasomaxillary complex, with or without mandibular retroposition. All children were concluded to have died of hypoxia during sleep. Our OSA children presented similar complaints and similar facial features. Anatomic risk factors for a narrow upper airway can be determined early in life, and these traits are often familial. Their presence should lead to greater attention to sleep-related complaints that may be

present very early in life and indicate impairment of well being and presence of sleep disruption. Further investigation should be performed to understand the role of upper airway infection in the setting of anatomically small airway in apparently abrupt death of infants and toddlers.

Keywords Abrupt death · Children · Naso-maxillary complex · Sleep-disordered breathing · Facial traits · Recognition of risk factors

Introduction

Pediatric sleep-disordered breathing (SDB) is most commonly related to a small upper airway. The nasomaxillary complex and the mandible are the bone structures supporting the soft tissues lining the upper airway. Adenotonsillectomy is the most common treatment of obstructive sleep apnea (OSA) in non-obese children, but this treatment approach can leave residual sleep-disordered breathing. Follow-up orthodontic treatment to widen the base of the nasomaxillary complex may further improve obstructive sleep apnea syndrome [3, 6–8, 22–24]. The clinical symptoms associated with OSA are well-documented and are multi-faceted, including agitated and disrupted sleep, parasomnias (sleepwalking, sleep terrors, enuresis, etc.), and noisy breathing at night, as well as daytime sleepiness, fatigue, morning headache, and learning, behavioral, and attention problems [9]. The facial features that are associated with anatomical risk factors for children with SDB have received more attention in the last few years. These facial traits are present at birth and may be features that run in the family. Environment during postnatal development also plays a role. Reports dating back to the mid-1960s have argued in favor of a continuous interaction between abnormal enlargement of the soft tissue of the upper airway, development of

C. Rambaud
Service d'anatomie pathologique et médecine légale Hôpital
Raymond Poincaré,
92380 Garches, France

C. Guilleminault (✉)
Stanford University Sleep Medicine Division,
Stanford Medical Outpatient Center,
450 Broadway, M/C5704,
Redwood City, CA 94063, USA
e-mail: cguil@stanford.edu

oral breathing, and abnormal growth of the nasomaxillary complex and mandible [11–15, 17, 27, 29]. Infants at birth are considered obligatory nasal breathers, and nasal breathing is the normal way to exchange air during sleep. However, in the setting of abnormal nasal resistance, a transition to mouth-breathing occurs at a variable age after birth; this is associated with an increase in respiratory effort during sleep. This increased effort leads to recruitment of accessory respiratory muscles during NREM sleep, but state-specific atonia eliminates this compensatory mechanism during REM sleep, a sleep state that represents a large proportion of total sleep time in the first year of life. Sleep position may have an impact on how effectively the intercostal muscles assist during periods of increased respiratory effort. Diaphragmatic placement with flattening of diaphragm when in a flat position may also have a role in breathing during sleep early in life. The recommendation to place infant on their back to sleep has been part of the well-known international “Back to Sleep” campaign [20]. Finally, the early position of the hyoid bone also affects stability of the airway. It is positioned at the level of the base of the tongue at birth, and slowly descends during early childhood towards the 4th vertebra.

The presence of a high and narrow hard palate is a clinical sign indicative of a narrow nasomaxillary complex and has been associated with presence of SDB and abnormal nasal resistance [8, 10, 19, 23]. Rapid maxillary expansion, an orthodontic treatment which may be used to treat OSA aims to widen this narrow and high hard palate in early childhood [2, 9, 13, 18, 24].

This report aims at attracting the attention of pediatricians on the importance of parental sleep complaints, and the anatomical features that were present in these infants that should have had these children considered as at risk of abnormal upper airway resistance during sleep and at risk of abrupt worsening during sleep in association with upper airway infection or inflammation.

Methods

We present a retrospective series of seven normal weight young children who are thought to have died during sleep between 2006 and 2008, and for whom death was determined to be “abrupt.” All of these children had post mortem evaluation in a forensic unit specializing in the investigation of abrupt deaths in infants and young children in the 92th department of France (western suburbs of Paris) depending of the city of Versailles Court and investigating judges. The unit utilizes a detailed protocol for investigation of abrupt death in young children, including thorough death scene investigation, investigation of the child’s health around the time of death (via pediatric records), review of the sleep

Table 1 Demographics and death reports of the presented children

	Case #1	Case #2	Case #3	Case #4	Case #5	Case #6	Case #7
Age at time of death	3 years, 4 months	9½ months	50 days	60 days	52 days	14½ months	22½ months
Gender	Female	Male	Male	Male	Male	Male	Male
Behavioral state prior to death	Asleep	Asleep	Asleep	Asleep	Asleep	Asleep	Asleep
Information on death before autopsy	Accidental Death	Accidental Death	Accidental Death	Accidental Death	Accidental Death	Accidental Death	Accidental Death
Autopsy findings related to cause of death	Accidental hanging	Accidental strangulation	Asphyxia during sleep, evidence of upper respiratory tract viral infection	Asphyxia during sleep, evidence of upper respiratory tract viral infection	Asphyxia during sleep, evidence of upper respiratory tract viral infection	Asphyxia during sleep, evidence of upper respiratory tract viral infection	Asphyxia during sleep, evidence of upper respiratory tract viral infection
Gestational age at birth	36 weeks (c-section; twin)	40 weeks (forceps)	40 weeks	37 weeks	37 weeks	40 weeks (heterozygote twin)	39 weeks

Table 2 Summary of past medical history

Past Medical History

Case #1	<ul style="list-style-type: none"> ▪ Breathing difficulties at birth ▪ Child kept 1 week in neonatology unit for observation—no treatment ▪ Rhinopharyngitis 24 h prior death
Case #2	<ul style="list-style-type: none"> ▪ Several episodes of rhinopharyngitis (never hospitalized) ▪ Rhinitis at time of death
Case #3	<ul style="list-style-type: none"> ▪ Unexplained fever at 3 weeks of age ▪ Possible viral infection
Case #4	<ul style="list-style-type: none"> ▪ None known
Case #5	<ul style="list-style-type: none"> ▪ None known
Case #6	<ul style="list-style-type: none"> ▪ Two episodes qualified as “bronchiolitis” more than 1 year before death ▪ (Viral) rhinopharyngitis 24-h prior death
Case #7	<ul style="list-style-type: none"> ▪ Several episodes of rhinopharyngitis ▪ One episode of bronchiolitis related to respiratory syncytial virus with hospitalization at 5 months of age ▪ Pharyngitis 24 h prior to death

Table 3 Summary of sleep history

Case #1	<ul style="list-style-type: none"> ▪ Chronic very agitated sleep, moved a lot during sleep ▪ Could often be found in head/feet opposite location and observed in many sleep positions due to agitated sleep. ▪ Known chronic snorer since at least 6 months of age.
Case #2	<ul style="list-style-type: none"> ▪ Chronic agitated sleep: Slept in many positions due to agitation during sleep. ▪ Mouth breathing during sleep ▪ Brief awakenings during sleep with short crying spells and falling asleep again on his own; no recall in morning. Mother initially concerned about crying spells but as problem was chronic and as there was rapid return to sleep without parental intervention, parents felt re-assured.
Case #3	<ul style="list-style-type: none"> ▪ Nothing reported by parents except night prior death except mouth breather during sleep possible rhinopharyngitis: Irritability, crying more than usual and waking-up more during night. Also may have had “faster breathing than usual” while asleep the evening before death ▪ Slept prone
Case #4	<ul style="list-style-type: none"> ▪ No report of abnormal sleep intermittent mouth breather ▪ Co-sleeping with mother ▪ Infant with regular breast-feeding schedule(3 to 4 h) ▪ Slept prone ▪ Presence of a “stuffy” nose within 36 h and more agitated sleep the night before
Case #5	<ul style="list-style-type: none"> ▪ Abnormal sleep noted by parent since first weeks of life ▪ Very long sleep periods and total sleep time that concerned mother ▪ Infant “hard to wake up” ▪ Nightly presence of intermittent snoring with mouth breathing ▪ Slow feeding: up to 60 min to finish bottle; needed repeated stimulation ▪ Slept supine
Case #6	<ul style="list-style-type: none"> ▪ Chronic “noisy” breathing during sleep but no real snoring, mouth breather during sleep. ▪ Child was brought to medical attention twice for “bronchiolitis” 14 months and 12 months before death (no treatment) ▪ Slept in variable positions including prone
Case #7	<ul style="list-style-type: none"> ▪ Very agitated sleep chronically ▪ Head position in maximum hyperextension during sleep since first few months of life ▪ Slept side/and many different positions every night for many months ▪ Had “cold” and “stuffy” nose last 30 h, sleep even more agitated night before death.

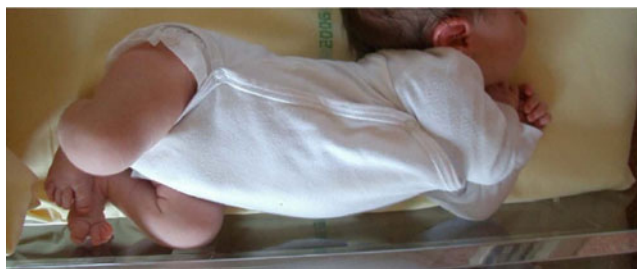

Fig. 1 Case #7: head position while sleeping through infancy. Legend: Note the head in hyperextension in the infant. The infant always slept in such position since 2 to 3 months of age. The position was so abnormal looking to parents that they photographed it and showed the photo to pediatrician. Such position is listed as an indicator of obstructive sleep apnea in a child in the *International Classification of Sleep Disorder 2nd ed.* Chronic snoring was present since 6 to 7 months of age

history from family and medical reports, and a thorough autopsy performed by a single forensic pathologist.

Subjects

The 7 children were selected from a larger pool of 15 children with abrupt sleep-time-related deaths and a high, narrow hard palate by a researcher outside of the forensic unit. These subjects were selected based on completeness of documentation of medical information prior death and presence of a sleep history with reports not limited to parental information, prior death. Two of the deaths (#1 and #2) were considered to be “accidental” at the death scene. The five others were considered to be abrupt and without clear explanation at the death scene.

Each dead individual was matched with a living same age and gender child monitored for sleep-disordered breathing and presenting a high and narrow vaulted palate and mouth breathing during sleep for comparison.

Table 4 Autopsy

Autopsy findings—upper airway	
Case #1	<ul style="list-style-type: none"> ▪ High and narrow hard palate (ogival palate) ▪ Abnormal mandibular retroposition ▪ Clear enlargement of tonsils ▪ Clear enlargement of adenoids ▪ Clear enlargement of cervical lymph nodes (2.5×1.5 cm) ▪ Very small upper airway
Case #2	<ul style="list-style-type: none"> ▪ High and narrow hard palate (ogival palate) ▪ Abnormal mandibular retroposition ▪ Clear enlargement of tonsils, particularly extending vertically ▪ Enlargement of cervical lymph nodes (2.5×1.5 cm) ▪ Small upper airway
Case #3	<ul style="list-style-type: none"> ▪ High and narrow hard palate (ogival palate) ▪ Abnormal mandibular retroposition ▪ Abnormal narrow nose with arrow internal nasal valves ▪ Small upper airway
Case #4	<ul style="list-style-type: none"> ▪ High and narrow hard palate (ogival palate) ▪ Deviated nasal septum ▪ Abnormal mandibular retroposition ▪ Auto visual pharyngitis and tracheo-laryngitis ▪ Small upper airway
Case #5	<ul style="list-style-type: none"> ▪ Narrow hard palate (ogival palate) ▪ Abnormal mandibular retroposition
Case #6	<ul style="list-style-type: none"> ▪ High and narrow hard palate (ogival palate)
Case #7	<ul style="list-style-type: none"> ▪ Abnormal mandibular retroposition ▪ Clear enlargement of cervical lymph nodes ▪ Small upper airway ▪ Narrow hard palate with abnormal mid-line sutures ▪ Abnormal mandibular retroposition ▪ Very voluminous tonsils ▪ Enlargement of cervical lymph nodes ▪ Small upper airway

Findings

Table 1 summarizes demographics and immediate death scene report, Table 2 summarizes the past medical history from medical reports, and Table 3 the known and documented sleep history.

Sleep history

Deaths occurred in a variety of contexts. Children #1 and #2 had accidental deaths. In subject #1, death was related to usage of a bed not meeting safety standards imposed by the European-Union. In subject #2, death occurred by strangulation by ties on the crib bumper pad. Already at death scene, there was mention that abnormal movements during sleep had lead to the condition setting up for the accident.

Deaths in subjects 1, 2, 5, and 7 occurred in the context of abnormal sleep which had been present for weeks to years. In these cases, there were histories of excessive movements during sleep, often associated with sweating. This “agitation” during sleep was significant enough to have been noted by each child’s parent and mentioned to pediatrician. Parents reported frequent position changes, tossing and turning, and/or finding the child rotated in bed with “feet on the pillow.” In one subject (#7), unusual sleep position was documented by a photograph at a much younger age, where he is shown sleeping with head in hyperextension a position noted by parents from very early age (Fig. 1). There was also some heterogeneity in parental interpretation of sleep quality, with some parents noting that excessive movements or short duration were out of the ordinary; while others did not note anything unusual. Other disturbances of sleep that occurred regularly were also interpreted as normal, such as nightly short and self-limited crying spells. Caregivers reported presence of chronic snoring or noisy breathing in subjects 1, 6, and 7. Another potential

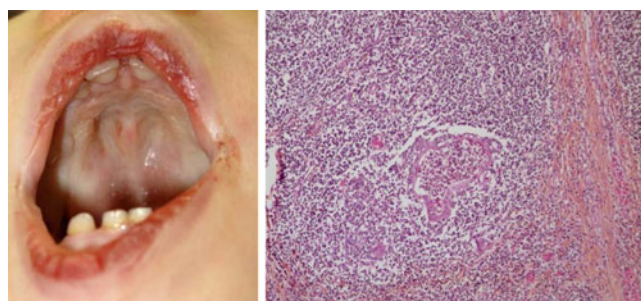


Fig. 2 Abnormal hard palate and acute tonsillar infiltration in Case #7. Legend: Note the abnormal presentation and narrowing of the hard palate, with presence of the two abnormal fossae, an anatomic risk factor for abnormal breathing during sleep. On the right side of the figure, histologic slide from tonsil with the presence of cryptic tonsil with polynuclear leucocyte infiltration and the presence of gram + infectious agent; the infection involves the tonsils that have secondary enlargement as noted at autopsy

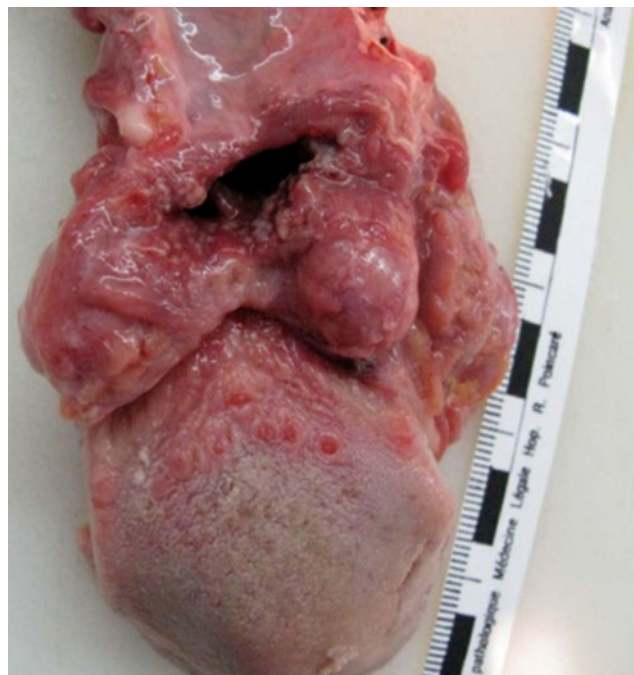

Fig. 3 Bilateral tonsillar enlargement in Case #2. Legend: This child had both a high and narrow hard palate as shown in Fig. 4 with large tonsils extending high in tonsillar fossae without evidence of acute infection. The child was a known mouth breather and was known to have very agitated sleep chronically often found with feet on pillow and head at bottom of bed due to movements. No report of snoring but self-limiting crying spells during sleep

sleep-related symptom involves excessive sleepiness including while feeding noted in subject #5, which led to several pediatrician visits that indicated normal neurological evaluation.

In summary, investigation of the sleep history demonstrated association with abnormal sleep in 6/7 subjects, with variable symptom types but sufficiently concerning to parents that they had been mentioned to the pediatrician at least once. These complaints, in the context of otherwise normal development of the child, did not raise significant concern.

Finally infant cases 3 and 4 were placed asleep usually in a prone position, as “they liked it more.”

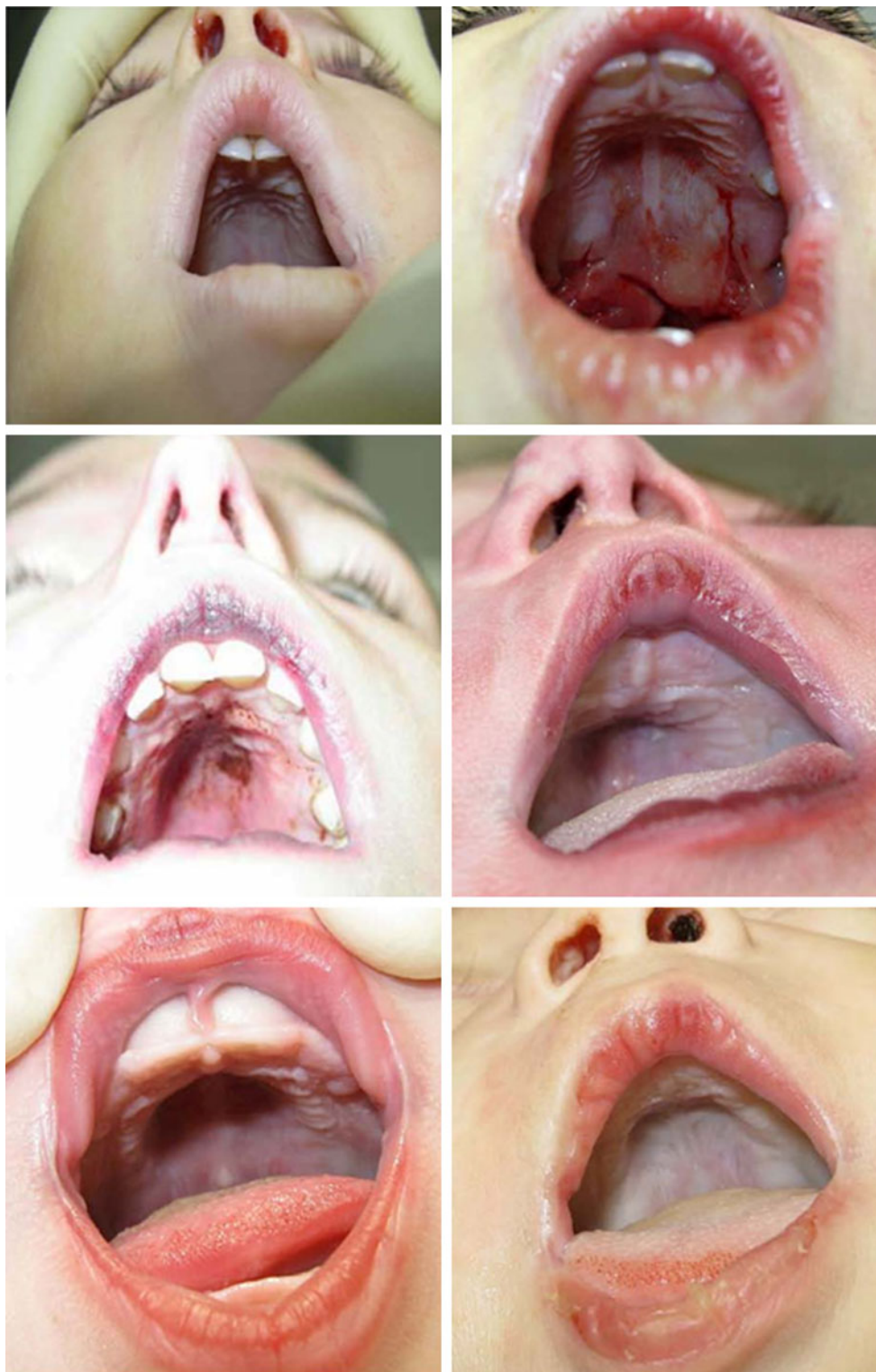Infection history

Half of the children were reported to have had symptoms of acute upper airway infection described as “pharyngitis” or “rhinopharyngitis” within the last 36 h of life. These reports were confirmed at autopsy.

Autopsy findings

Table 4 summarizes major autopsy findings, particularly in the upper airway. Presence of acute infection was confirmed in the above-mentioned subjects. The most dramatic was subject #7, in whom a Gram positive infection of the upper

Fig. 4 Montage of abnormal high and narrow hard palate in Cases #1–6. Legend: Note that all children present a visually recognizable abnormal high and narrow hard palate which is related to the development of the naso-maxillary complex during embryonic development considering age of children. On the first row on the left, on the second row in both cases, and on the third row from the top on the right; note the abnormal noses presented by the patients. The asymmetry of the nostril may not be obvious at first investigation; using photographs taken below the nose may help performing quietly better analyses. Asymmetrical opening is often associated with asymmetrical septum and change in nasal resistance. When associated with high palatal vault, they indicate presence of a higher upper airway resistance and greater risk of abnormal breathing during sleep with addition of infectious or inflammatory reaction (see text)



airway was identified, associated with active inflammatory infiltration of the tonsils (Fig. 2) associated with edema and enlargement of the surrounding soft tissues. In general, parents did not find upper airway infection symptoms alarming, and in the two cases in which a pediatrician had been consulted, only reassurance was given. There were also

clearly enlarged tonsils without evidence of acute infection in subject #2; these tonsils were noted to be both wide and elongated (Fig. 3). This was associated with the presence of small mandible, a finding often associated with narrow naso-maxillary complex (Fig. 4). All infants died with signs of important hypoxia at autopsy (Fig. 5).

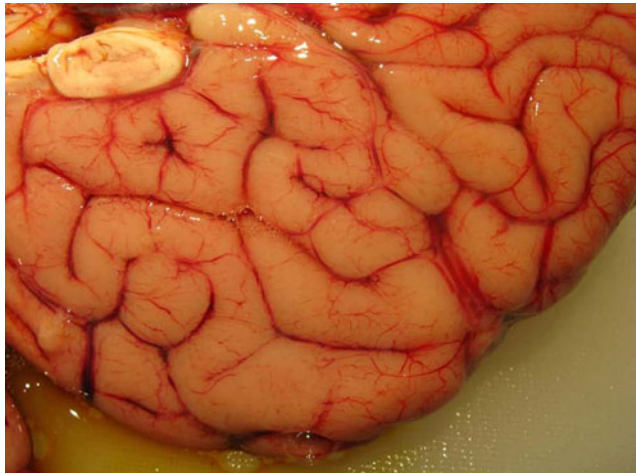


Fig. 5 Brain. Legend: Slice of brain demonstrating presence of important brain edema consequence of important hypoxia before death

Living children

From previously seen children with sleep-disordered breathing, seven children were extracted from the data base, they must have had clinical and oropharyngeal evaluation and polysomnography and be an age and gender match for the dead children. Anonymous data were then compared to the facial-oropharyngeal anatomic reports from those of the dead children, and those most closely related from the reports were considered as matching living children (Fig. 6). Each of the children had been seen and had a polysomnography—PSG—at the sleep-disordered clinic. PSG was obtained during daytime nap in infants 3 months and younger, nocturnal PSG was performed in all other cases. Retrospective analysis of de-identified clinical and polysomnographic data was approved by Stanford IRB.

Children younger than 6 months were seen for noisy/snoring during sleep, and history of caretaker having observed abnormal breathing with presence of a “stopped breathing event” during sleep. The older children were seen for agitated sleep, snoring, difficulty to wake-up in the morning, and irritability; night terrors ($n=2$) inattention and hyperactivity ($n=1$), and daytime sleepiness and “lethargy” ($n=3$). Table 5 present these 7 matched living individuals and summarize the anatomical and PSG findings confirming presence of sleep-disordered breathing (see Table 5)

In summary: all children, dead and alive, presented a similar history of abnormal sleep; they also had similar anatomical oropharyngeal findings at examination. The abrupt death occurred in presence of a similar pathological background. Abnormal breathing during sleep was demonstrated with documentation of SDB on polysomnography in the living children who were treated. The dead children were not recognized as having abnormal sleep and were left untreated. Death was associated with most commonly an

upper airway infection and impairment of nasal breathing. It was related to the very chronic agitated sleep in two and presence of unsafe bedding in the “accidental deaths.”

Discussion

Although the exact sequence of events in these sudden, sleep-time-related pediatric deaths remains unknown, many of the deaths were preceded by an abnormal sleep history combined with anatomical risk factors for abnormal breathing during sleep. Also, it is unknown what role agitated sleep may have played in the two accidental deaths, though we conjecture that reduction of agitation during sleep periods may have reduced the likelihood of accidents. The consequences of abnormal breathing during sleep with very agitated sleep—well documented by interviews of several caregivers of the same child—were a risk factor for an accident if bedding conditions were inappropriate.

All deaths showed evidence of hypoxia at time of death without other underlying causes (Fig. 5), and as mentioned above, all cases were associated with anatomical risk factors for abnormal breathing during sleep. In some cases, acute infection that further enlarged the soft tissues may have also

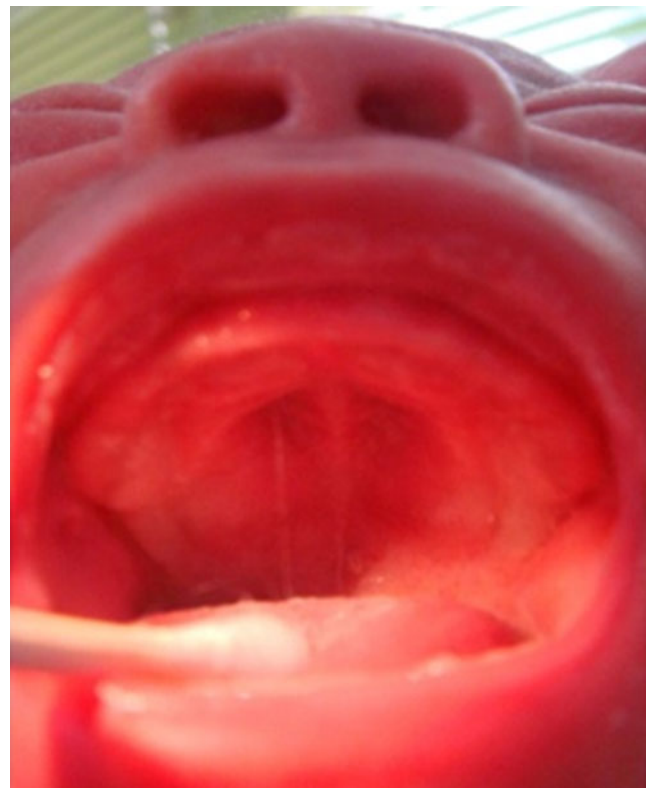


Fig. 6 Palate of a living infant with ALTE. Legend: Report of apparent life threatening event and presence of obstructive sleep apnea at polysomnography. Note the abnormal palatal vault presented by this infant similar to the one noted in the dead infants

Table 5 Demographics, results of evaluation, and polysomnographic findings in control living children

Case #1 control; age: 42 months	<ul style="list-style-type: none"> ▪ High, arched, and narrow hard palate (ogival palate) ▪ Abnormal mandibular retroposition ▪ Small upper airway 	<ul style="list-style-type: none"> ▪ AHI=10 ▪ Lowest SaO₂=90 % ▪ Snoring 100 % time with presence of flow limitation
Case #2 control; age: 10 months	<ul style="list-style-type: none"> ▪ High, arched, and narrow hard palate (ogival palate) ▪ Abnormal mandibular retroposition ▪ Small upper airway 	<ul style="list-style-type: none"> ▪ AHI=13 ▪ Lowest SaO₂=89 % ▪ Snoring 100 % time with flow limitation
Case #3 control; age: 6 weeks	<ul style="list-style-type: none"> ▪ High, arched, and narrow hard palate (ogival palate) ▪ Mandibular retroposition ▪ Small upper airway 	<ul style="list-style-type: none"> ▪ AHI=2 lowest SaO₂=96 %, mouth breathing, snoring
Case #4 control; age: 9 weeks	<ul style="list-style-type: none"> ▪ High, arched, and narrow hard palate ▪ Mandibular retroposition ▪ Small upper airway 	<ul style="list-style-type: none"> ▪ AHI=2.6, lowest SaO₂=94 % ▪ Mouth breathing, presence of flow limitation (ogival palate)
Case #5 control; age: 7 weeks	<ul style="list-style-type: none"> ▪ High, arched, and narrow hard palate (ogival palate) ▪ Mandibular retroposition ▪ Small upper airway 	<ul style="list-style-type: none"> ▪ AHI=5, lowest SaO₂=92 % ▪ Mouth breathing with flow limitation
Case #6 control; age: 12 months	<ul style="list-style-type: none"> ▪ Narrow hard palate (ogival palate) ▪ Mandibular retroposition ▪ Enlarged tonsils 3+ 	<ul style="list-style-type: none"> ▪ AHI=9 lowest SaO₂=90 % ▪ Continuous mouth breathing and snoring
Case #7 control; age: 22 months	<ul style="list-style-type: none"> ▪ High, arched, and narrow hard palate (ogival palate) ▪ Mandibular retroposition ▪ Small upper airway ▪ Tonsils 2+ but elongated, vertical expansion 	<ul style="list-style-type: none"> ▪ AHI=14 lowest oxygen saturation; 89 %, ▪ Continuous mouth breathing and snoring with flow limitation

contributed to the development or worsening of abnormal breathing during sleep leading to even more agitated sleep. The sleep with head in hyperextension as presented in Fig. 1 is listed in the “International Classification of Sleep Disorder” as a sign of obstructive sleep apnea in children [1] and many of the symptoms mentioned by parents (sweating at night, agitated sleep, chronic snoring, and even chronic noisy breathing) [5, 9] have been cited as associated to abnormal breathing during sleep in general reviews of child OSA. The reports from the families were also very similar to those of our matched living OSA children.

Tachypnea is also a well-known finding in polysomnographic recordings of young children with sleep-disordered breathing [3]. It may be seen even without associated hypopneas or apneas during sleep and may also be associated with clinical symptoms that disappear after adenotonsillectomy. Tachypnea is a response to maintain minute ventilation if tidal volume is acutely decreased for any reason. But such a response has known limitations and may not be sufficient, particularly during REM sleep with the physiological disappearance of the respiratory accessory muscles due to the sleep state muscle atonia to avoid development of hypoventilation. Sleep position (prone) may be a further disadvantage. The

association between prone position and abrupt death during sleep in infants is well documented as is often the report of a mild upper airway infection. Children with well-documented SDB prefer to sleep in a prone position, extending their head, and thus opening more their upper airway during sleep. It is recognized that an abnormally small upper airway may at times be seen in young infants previously considered as “near-miss SIDS/ALTE” or even “SIDS” [6, 11, 23].

The role of mild anatomical facial features in infants and abnormal breathing during sleep has been evoked for a long time, and has been link to need to resuscitation during sleep in infants and abrupt death classified as “SIDS” [6, 11, 21–23, 25, 26]. The facial traits that are related to the size of the upper airway may add a risk factor to poor breathing during sleep if an acute event involving decrease in air intake occurs including change in diaphragm position at rest while asleep. Modification of possible amplitude of thoracic movement depending of sleeping position in very young infant, may add to any, even limited, nasal resistance related to an acute nasal infection. One has also to emphasize of that two the infants presented not only a narrow hard palate, but also had an abnormal nasal presentation. Such combination of facial problems (narrow palate and abnormal nasal

passages) increases nasal resistance and renders children even more susceptible to abnormal nasal breathing with even modest rhinitis. Insufficiencies of the bony nasomaxillary complex and/or mandible are risk factors for abnormal breathing that may be present at birth [4].

The soft tissues of the upper airway are important factors in a normal size upper airway. In marginal cases, an abrupt enlargement of the soft tissues leading to an abrupt increase in nasal resistance leads to further airway narrowing and further reduce gas exchange, particularly again with physiologic muscle atonia of REM sleep. Recognition of risk factors leading to narrow upper airway as early in life as possible is important. High and narrow hard palate can be seen at/or very close from birth, the narrowing may also develop over time, particularly if there is a hypotonia of the tongue and facial muscles. Abnormal contraction of genio glossus and facial muscles has been experimentally demonstrated in infant monkeys where increase nasal resistance is induced [16], so, abnormality of the nose may induce abnormal nasal resistance that may secondarily impact maxillary growth [16]. Pediatricians have to understand the continuous interaction between good upper airway air-exchange-normal maxillary growth and normal nasal resistance. They may have to pay attention to minor abnormalities of the nostrils as seen in four of our dead infants (see Fig. 4), abnormal septum placement, and high and narrow palatal vault. Polysomnography may not show apnea or hypopnea but “flow limitation” as previously defined [8]. Research investigation with the new standard for active anterior rhinometry (four-phase high resolution rhinomanometry) and acoustic rhinometry may be research tools to investigate further these infants [25, 28].

In this series, most dead children had additional contributing elements, such as upper airway infection. Tonsils were clearly enlarged at autopsy in several cases, providing a different source of functional upper airway narrowing. When examining the upper airway of a child, attention should be given to both soft tissue and bony limits of the upper airway. Those recognized to have small upper airways should be carefully evaluated, in particular during upper airway illnesses. Education of pediatrician and obstetricians on facial features of poor breathing during sleep may be helpful.

Acknowledgments We greatly thank Shannon S. Sullivan, M.D. for her help in the preparation of this manuscript.

Conflict of interest None of the authors has conflict of interest.

References

1. American Academy of Sleep Medicine (AASM) (2005) The international classification of sleep disorders, diagnostic and coding manual, 2nd ed. AASM Westchester IL; pp 56–59
2. Cistulli PA, Palmisano RG, Poole MD (1998) Treatment of obstructive sleep apnea-syndrome by rapid maxillary expansion. *Sleep* 21:831–835
3. Cohen SR, Ross KA, Burstein FD, Lefaivre JF, Riski JE, Simms C (1998) Skeletal expansion combined with soft-tissue reduction in the treatment of obstructive sleep apnea in children: physiologic results. *Otolaryngol Head Neck Surg* 119:476–485
4. Enlow DH (1990) Poston WR, Facial Growth 3rd ed. Philadelphia Saunders
5. Guilleminault C, Korobkin R, Winkle R (1981) A review of 50 children with obstructive sleep apnea syndrome. *Lung* 159:275–287
6. Guilleminault C, Heldt G, Powell N, Riley R (1986) Small upper airway in near miss SIDS infants and their families. *Lancet* 1:402–407
7. Guilleminault C, Partinen M, Praud JP, Quera-Salva MA, Powell NB, Riley RW (1989) Morphometric facial changes and obstructive sleep apnea in adolescent. *J Peds* 114:997–999
8. Guilleminault C, Li KK, Khramtsov A, Pelayo R, Martinez S (2004) Sleep disordered breathing: surgical outcome in prebutertal children. *Laryngoscope* 114:132–137
9. Guilleminault C, Lee JH, Chan A (2005) Pediatric obstructive sleep apnea syndrome. *Arch Pediatr Adol Med* 159:775–785
10. Guilleminault C, Huang YS, Glamann C, Li K, Chan A (2007) Adenotonsillectomy and obstructive sleep apnea in children: a prospective survey. *Otolaryngol Head Neck Surg* 136:169–175
11. Gun R, Tonkin SL (1989) Upper airway measurement during inspiration and expiration in infants. *Pediatrics* 84:73–74
12. Gun JR, Tonkin SL, Hadden W, Davis SL, Gunn AJ (2000) Neonatal micrognathia is associated with small upper airway radiographic measurements. *Acta Pediatr* 89:82–87
13. Leech HA (1958) Clinical analysis of orofacial morphology and behavior of 500 patients attending an upper respiratory clinic. *Dent Pract Dent Res* 9:57–68
14. Linder-Aronson S (1969) Dimensions of face and palate in nose breathers and habitual mouth breathers. *Odont Rev* 14:187–200
15. Linder-Aronson S (1970) Adenoids. Their effect on mode of breathing and nasal airflow and their relationship to characteristics of the facial skeleton and the dentition. A biometric, rhino-manometric and cephalometro-radiographic study on children with and without adenoids. *Acta Oto-Laryngologica Supp* 265:1–132
16. Miller AJ, Vargevik K, Chierici C, Harvold E (1984) Experimentally induced neuromuscular changes during and after nasal airway obstruction. *Am J Orthod* 85:385–392
17. McNamara JA (1981) Influence of respiratory pattern on craniofacial growth. *Angle Orthod* 51:269–300
18. Pirelli P, Saponara M, Guilleminault C (2004) Rapid maxillary expansion in children with obstructive sleep apnea. *Sleep* 27:761–766
19. Pirelli P, Saponara M, Da Rosa C, Ezio F (2010) Orthodontics and obstructive sleep apnea in children. *Med Clin North Am* 94:517–530
20. Rambaud C, Guilleminault C (2004) “Back to sleep” and unexplained sudden death in. *Sleep* 27:1359–1368
21. Rees K, Right A, Keeling JW, Douglas NJ (1998) Facial structure in the sudden infant death syndrome: case-control study. *BMJ* 317:179–180
22. Tasker C, Crosby JH, Stradling JR (2002) Evidence for persistence of upper airway narrowing during sleep, 12 years after adenotonsillectomy. *Arch Dis Child* 86:34–37
23. Tauman R, Gulliver TE, Kirshna J, Montgomery-Down HE, O’Brien L, Ivannenko A, Gozal D (2006) Persistence of obstructive sleep apnea syndrome in children after adeno-tonsillectomy. *J Pediatr* 149:803–808
24. Timms DJ (1984) The reduction of nasal airway resistance by rapid maxillary expansion and its effect on respiratory disease. *J Laryngol Otol* 98:357–362
25. Toh ST, Lin CH, Guilleminault C (2012) Usage of four-phase high resolution-rhinometry and measurement of nasal resistance. *Sleep-Disordered-Breathing Laryngoscope* (in press)

26. Tonkin SL, Davis SL, Gunn AJ (1994) Upper airway radiography in infants with upper airway insufficiency. *Arch Dis Child* 70:523–529
27. Vieira BB, Itikawa CE, de Almeida LA, Sanders HS, Fernandes RMF, Anselmo-Vilma WT, Valera FCP (2011) Cephalometric evaluation of facial pattern and hyoid bone position in children with obstructive sleep apnea. *Int J Pediatr Otolaryngol* 75:383–386
28. Vogt K, Jalowayski AA (eds) (2010) 4-Phase-rhinomanometry: basics and practice. *Rhinology Suppl* 21:3–48
29. Zettergreen L, Linder-Aronson S, Norlander B, Agren K, Svanborg E (2002) Longitudinal effect on facial growth after tonsillectomy in children with obstructive sleep apnea. *World J Orthod* 3:67–72