

# It's time to talk about Myofunctional Therapy

By Dr Rohan Wijey, BOralH (DentSci), Grad.Dip.Dent (Griffith), OM



*"Why didn't it take off? It simply didn't work. The traditional way of delivering exercises to kids with a practitioner talking at a child for 30-45mins was not financially expedient and was also an abjectly ineffective way to educate patients..."*

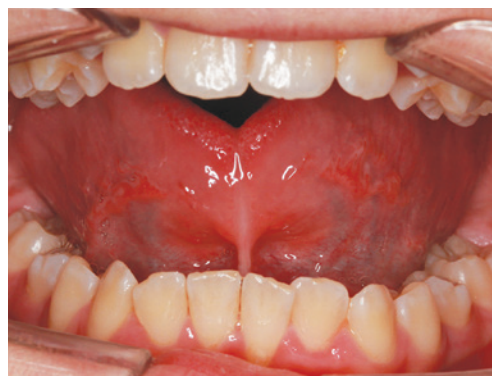**M**yofunctional Therapy has enjoyed a resurgence in recent years, but what is its evidence base, what are its goals and who is actually licensed to deliver it in Australia? The following article covers a series of FAQ's to give you up-to-date knowledge in this ground-breaking field.

## What is Myofunctional Therapy?

**M**yofunctional Therapy usually consists of a series of exercises targeting orofacial muscles in an attempt to establish their proper posture and function. These dysfunctions may be termed, "Oro-facial Myofunctional Disorders" (OMDs), "Soft Tissue Dysfunction", "Tongue-Thrust Swallow", "Infantile Swallow" or "Reverse Swallow".

## What causes Orofacial Myofunctional Disorders (OMDs)?

**B**efore contemplating the cause of OMDs, it is apposite to first establish the correct posture and function of the orofacial muscles. Despite debate as to its bearing on craniofacial development, most dental practitioners accept that the correct resting posture of the tongue is in the palate with the lips resting together. It follows that in the



*Figure 1. Anterior and submucosal tongue-tie in a 10-year-old patient.*

event of nasal resistance or obstruction that leads to mouth breathing, the tongue must descend from the palate and the lips separate to allow passage of air. Apart from the effects on the resting postures of the associated muscles, a dysfunctional swallow also tends to form. This is due to the fact that a correct swallow depends on contact of the anterior, middle and even part of the posterior dorsum of the tongue on the palate; if the tongue thrusts anteriorly ("tongue-thrust"), remains lowered or simply does not make sufficient dorsum-to-palate contact, orofacial muscles are recruited to compensate. In general terms, the muscles of mastication, rather than of facial expression, should be recruited during a correct swallow.

## Diet

Since development of masticatory muscles has a large bearing on the function of a swallow, an obvious factor to be considered is the texture of our diets. Weiland et al (1997) compared skulls from 19th century Austrian males with their contemporaries, finding that change in diet ensured the latter displayed significantly higher malocclusion scores.<sup>1</sup> Corruccini and Lee (1984) reported that malocclusion was significantly worse in Chinese children born in the UK compared to their immigrant parents, raised in less developed areas; since genetic factors remained unchanged, the malocclusion in the offspring was attributed to diet, premature deciduous tooth loss from caries and oral respiration (mouth breathing).<sup>2</sup> Corruccini and Beecher (1981, 1983, 1984) have also shown that a soft diet significantly increases dental and skeletal malocclusions in rats, macaques and primates.<sup>3</sup> This, again, is most likely due to less tonicity in muscles of mastication, resulting in compensatory overactivity in muscles of facial expression.

## Mouth breathing

The prevalence of mouth breathing in large population studies amongst young children is over 50%. Allergic rhinitis is the largest cause of mouth breathing, affecting around two thirds of these patients and hypersensitivities to dust, mould and animal hair are the most commonly found allergens.<sup>4</sup> Some authors also highlight enlarged adenoidal tissue and tonsils as important causes of airway obstruction<sup>5</sup> the prevalence of this can be approximately 30%.

## Breast- vs bottle-feeding

A number of studies have demonstrated opposite effects on the predictability of certain malocclusions, when comparing breast- to bottle-fed kids.<sup>6</sup> During breast-feeding, the tongue must compress the areola against the palate, which not only imparts direct force for maxillary development, but also works to strengthen the 16 muscles in the tongue's blade, to help establish proper long-term tongue posture. Bottle-feeding, however, doesn't require the same complex series of tongue movements as there is a constant flow from the teat.

## Tongue-tie

The art and science of diagnosing extended lingual frenums is seeing a fervently-paced evolution, that is (perhaps concerning) being matched with an explosion in inexperienced practitioners performing frenectomies. There is no well-validated clinical evaluation method in the literature, however, a recent clinical review pits the prevalence between 4% and 10% of the general population.<sup>7</sup> A severe anterior tongue-tie is relatively simple to diagnose, but there is currently a lack of consensus as to the point at which a submucosal (commonly known as "posterior") attachment requires surgery. Another issue is that the

Despite all this, frenectomies are of course required at times. From a myofunctional perspective, if the posterior dorsum of the tongue cannot contact the palate during a swallow, it is near-impossible to completely deactivate a reverse swallow.

Figure 1 shows a 10-year-old tongue-tied patient. The resultant low tongue posture led to a narrow upper arch form and high palatal vault. On completing the frenectomy and re-training the tongue posture with a myofunctional appliance, the palatal vault has undergone considerable remodelling.

## Adverse effects of Orofacial Myofunctional Disorders (OMDs)?

### Mouth breathing and its effect on craniofacial development

Trailing its American counterparts in the American Association of Orthodontists (AAO) by about 20 years, our Australian Society of Orthodontists (ASO) now also recognises the role of mouth breathing in malocclusion and craniofacial development; it now advocates early examination and sometimes treatment, by the age of 8 (Figure 2). However, concern about airway and Sleep-Disordered Breathing (SDB) demands scrutiny much earlier, since 80% of craniofacial development is attained by the age of 5-6 years.<sup>8</sup> Rogers (2006) says that if treated late, paediatric OSA may lead to "significant morbidity... which may not be completely reversible".<sup>9</sup>

ENT specialists have long accepted the effects of mouth breathing on craniofacial development, describing the phenomenon as "Adenoid Facies" or "Long-Face Syndrome". In fact, Danish ENT, Wilhelm Meyer, first described the different facial appearances in his patients with breathing disorders as early as 1868.<sup>11</sup>

## Orthodontic relapse

In a sweeping review on the subject incorporating 40 years' worth of articles, Bondemark found that the tenor of the debate on orthodontic relapse rested with which retention regimen is most effective.<sup>12</sup> The fact that the hot question in orthodontics is whether bonded or

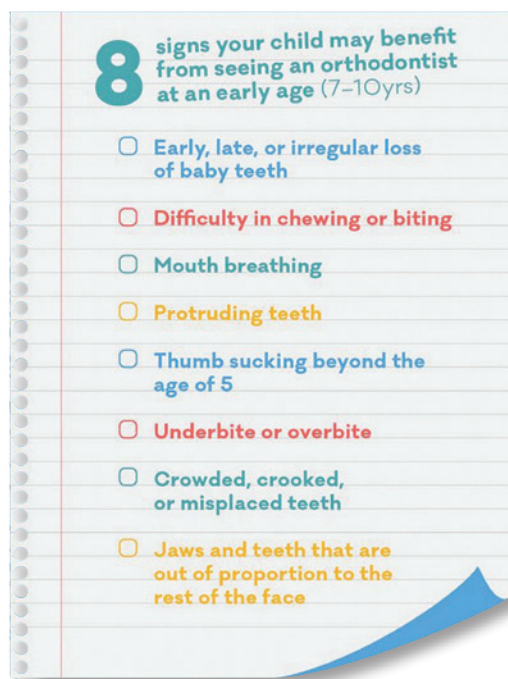


Figure 2: The ASO now recognises the role of mouth breathing in the development of malocclusion.<sup>10</sup>

increase in frenectomies being performed by dentists has unfortunately not necessarily seen a commensurate increase in technique or skill level. Especially for a submucosal attachment, it seems the laser and "sweeping" or "stretching" procedure often does not yield satisfactory results for healing or prevention of reattachment. Furthermore, "sweeping", which is a euphemism to describe agitating the site of the exposure for a week after the procedure, carries ethical and medico-legal questions; is it reasonable to expect a parent to perform this unsubstantiated procedure unsupervised and uneducated in basic principles of healing?

removable retainers are more effective, is a sad indictment on the current state of affairs. The flavour of the studies must shift towards the causative factors behind relapse and its subsequent prevention.

Although most practitioners now realise the only aspect of traditional orthodontics that is predictable is its unpredictability, there somehow exists a common misconception that orthognathic surgery is the

factor in relapse of mandibular setback. In his review of open bite treatment, Shapiro (2002) suggests that the high rate of instability with or without surgery is most likely due to “non-adaption of the tongue”. In their review of the orthodontic influence of mandibular muscles, Pepicelli et al. (2005) corroborate it is “well accepted” that the position and function of the facial and mandibular muscles are

Similar to the resurgence it is experiencing today, OMT was all the rage in the orthodontic world in the USA in the 1970s, when everyone suddenly remembered its sound theoretical and biological principles. Why didn’t it take off? There was no nefarious scheme by some orthodontists as some would like to suggest. It simply did not work. The traditional way of delivering exercises to kids with a practitioner talking at a child for 30–45mins was not financially expedient and was also an abjectly ineffective way to educate patients. There exists a striking homogeneity in approach across the world when it comes to OMT and this approach has been based on the speech pathologist, Daniel Garliner’s, textbook from the 1970s. The approach did not work then as it does not work now. The current Twitter and Snapchat world has ensured the modern child’s attention span and preference in the way they digest information is simply at odds with traditional OMT.

Furthermore, most OMTs have only completed one 4-day course, meaning it is not a “qualification” that should carry any credibility.

### Is myofunctional therapy legal in Australia?

It is outside the scope of practice for dental hygienists or oral health therapists to conduct OMT in Australia. Many still do and pretend they are “taking their dental hat off” and treating patients independent of their professional qualification. Myofunctional therapy is not a recognised science in Australia and therefore, theoretically, anyone can perform it, apart from those with a professional dental qualification.

### Can you use myofunctional appliances?

Yes. AHPRA has indicated Myobrace®, in particular, is perfectly acceptable.

### What does the future hold for myofunctional therapy?

We know that the outdated practices from the 1970s have not worked in a financial or therapeutic sense, however, we do know that myofunctional appliances have been proven as the most effective way to deliver OMT to patients for 30 years.

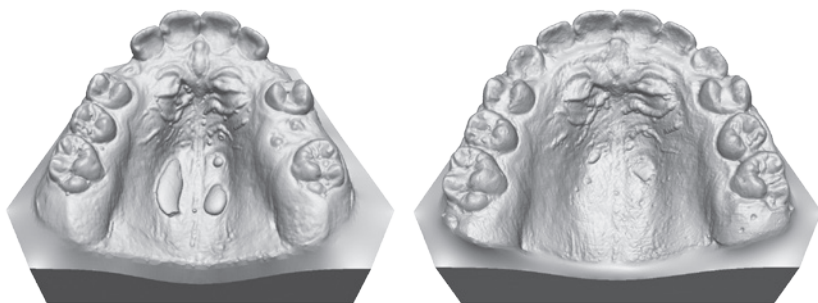


Figure 3. The palatal vault has remodelled due to The Myobrace System encouraging correct tongue rest posture. Myofunctional exercises alone are not powerful enough to elicit such changes; these must always be combined with a myofunctional appliance.

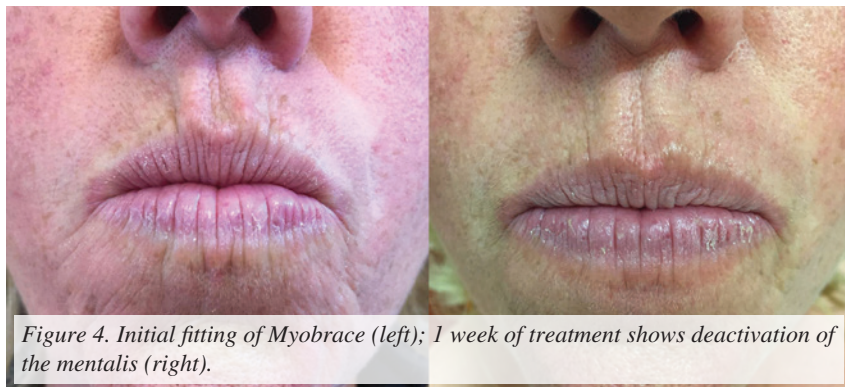

Figure 4. Initial fitting of Myobrace (left); 1 week of treatment shows deactivation of the mentalis (right).

definitive answer to a skeletal discrepancy; what does the evidence suggest? In 2007, Proffit amassed an impressive volume of data on the subject, involving over 100 research articles and 2,264 patients. He found the rates of relapse “surprising”, with some procedures experiencing a “moderate” or “highly significant” change in up to 80% of patients.

If even surgery is no match for relapse, which of the aforementioned factors has the power to reshape and remodel bone?

“Whenever there is a struggle between muscle and bone, bone yields”, wrote Graber in his seminal 1963 manifesto on the influence of muscles on malformation and malocclusion. An expansive literature review<sup>13</sup> found a major factor that may affect post-treatment stability is the neuromusculature and Chang et al. (2006) regarded muscular forces as the principle

“critical influences” on alignment and stability. These include a dysfunctional swallow and incorrect tongue posture.

### Is myofunctional therapy evidence-based?

No. Does this make it an invalid treatment approach? Almost, but not completely. A current search of the keyword “myofunctional” in the American Journal of Orthodontics and Dentofacial Orthopedics (AJODO) database yields 19 articles; only 3 of these were published in the last 40 years. There is not much of an evidence base underpinning OMT when it comes to orthodontics. The evidence base, however, is completely different when it comes to SDB and Guilleminault’s work in Stanford deserves special attention.

Now to the elephant in the room.



MRC has produced the Myobrace Activities, which is an interactive app for Android and iOS compatible devices complete with 3D video animations and quizzes to revolutionise the delivery of this information to your patients. This is now the most widely-used program of OMT in the world and removes many of the logistical hindrances in regards to expertise and patient engagement that are still a reality in the traditional myofunctional therapy world.

### Myofunctional case report 1

A 50-year-old female presented for orthodontic treatment. Figure 4 shows the initial fitting of the Myobrace for Adults A1 appliance on the left. As is often the case prior to treatment, the orbicularis oris is too weak to establish lip seal without a compensatory activation of muscles of facial expression; in this case, the paired mentalis muscle group is overactivated. The right image of Figure 4 shows the myofunctional change just one week later. The Myobrace A1, together with the Lip Trainer and Myobrace Activities, worked to increase lip strength, thereby deactivating the orofacial muscular activity.

### Myofunctional case report 2

A 9-year-old male was a severe mouth breather, whose lower lip trap flared his upper central incisors. His severe mentalis activity limited the proper development of his mandible, leaving him with a significant overjet. In a case such as this, a program of myofunctional exercises alone will be of little benefit. Figure 5 shows that after use of the Myobrace K-series, together with Myobrace Activities and the Lip Trainer, the results are positive; however, all the more striking given that the changes were driven by a change in breathing and muscle function, rendering the results (at least theoretically) more stable. The most pleasing result, however, is for the patency of the airway, which has increased due to the antero-posterior (A-P) displacement of the maxilla and mandible (Figure 6).

*To find out more information about how to begin implementing The Myobrace System and begin experiencing increased patient volume visit [myoresearch.com](http://myoresearch.com).*

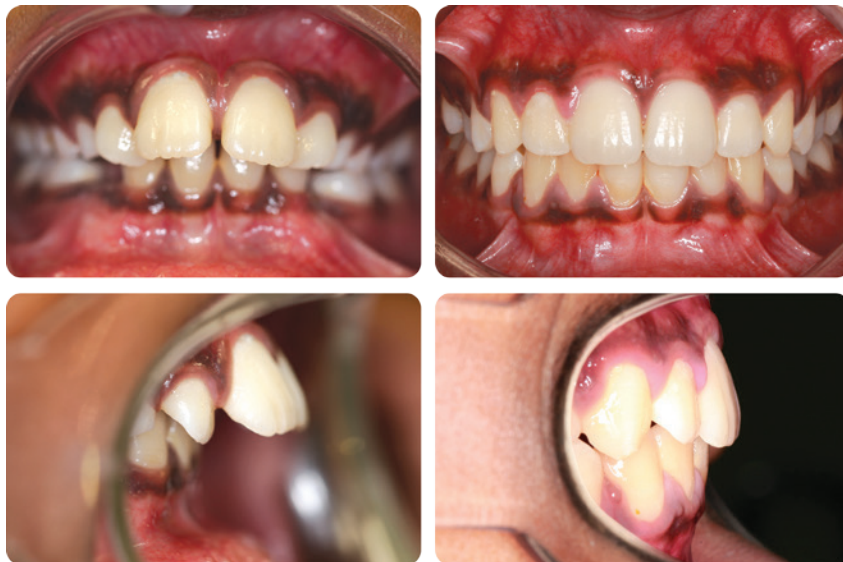

Figure 5. A significant change in the occlusion and alignment is not possible with exercises alone; a myofunctional appliance system is vital to elicit such changes.

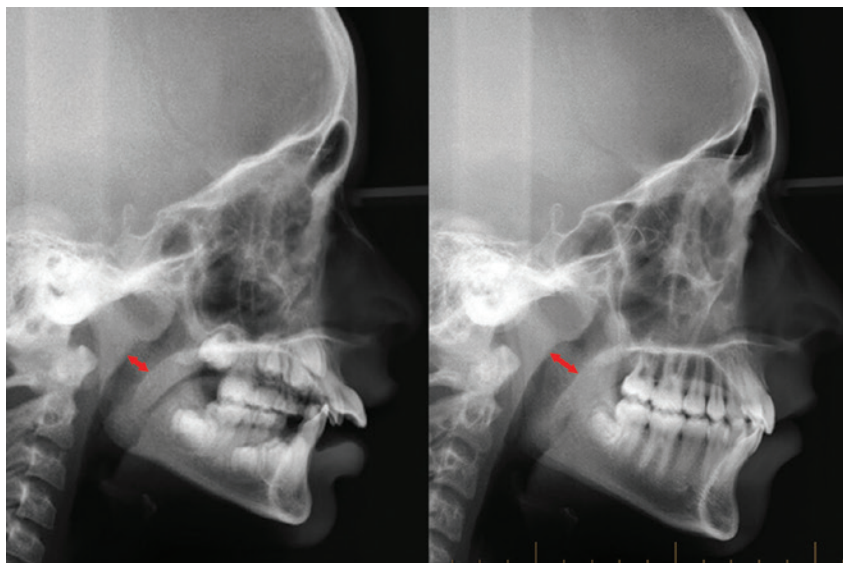


Figure 6. Treating Orofacial Muscular Disorders (OMDs) with the Myobrace System resulted in an increase in airway patency, due to A-P maxillo-mandibular displacement.

### References

- Weiland FJ, Jonke E, Bantleon HP. Secular trends in malocclusion in Austrian men. *Eur J Orthod* 1997; 19: 355-9.
- Corruccini RS, Lee GTR. Occlusal variation in Chinese immigrants to the United Kingdom and their offspring. *Arch Oral Biol* 1984; 29: 779.
- Beecher RM, Corruccini RS (1981) Effects of dietary consistency on craniofacial and occlusal development in the rat. *The Angle Orthodontist*; Beecher RM, Corruccini RS (1983) Craniofacial correlates of dietary consistency in a nonhuman primate. *Journal of craniofacial*; Corruccini RS (1984).
- Abreu RR et al. Etiology, clinical manifestations and laterations present in oral breathers. *Journal of Pediatrics* 2008; 84:6.
- Di Francesco RC, Passerotti G, Paulucci B, Miniti A. Oral breathing in the child: different repercussions according to the diagnosis. *Rev Bras Otorrinolaringol*. 2004; 70: 665-70.
- Romera CC et al. Breastfeeding and non-nutritive sucking patterns related to the prevalence of anterior open bite in primary dentition. *J. Appl. Oral Sci*. 2011; 19 (2).
- Segal LM. Prevalence, diagnosis, and treatment of ankyloglossia. *Can Fam Physician* 2007; 53.
- Aknin JJ. Croissance du massif facial supérieur in La croissance cranio-faciale. Paris: SID Publ; 2007 in Guilleminault C, Akhtar F. Pediatric sleep-disordered breathing: New evidence on its development. *Sleep Medicine Reviews* 2015; 24.
- Rogers R. Sleep, Breathing and Orthodontics. *Sleep Review* 2006; 29(2) 240-243.
- [<https://www.aso.org.au/benefits-early-treatment>] Accessed 23 July 2017.
- Thornval A. Wilhelm Meyer and the adenoids. *Arch Otolaryngol* 1969; 90: 383-386.
- Bondemark L, Holm A-K, Hansen K, Axelsson S, Mohlin B, Brattstrom V, Paulin G, Pietila T (2007) Long-term stability of orthodontic treatment and patient satisfaction. A systematic review. *Angle Orthod* Vol. 77, Issue 1, pp.181-91.
- Blake M, Bibby K (1998) Retention and stability: A review of the literature. *American Journal of Orthodontics and Dentofacial Orthopedics* Vol. 114, No. 3.